

# Anorectal Disorders

*Adil E Bharucha*

## Fecal incontinence

### Introduction and epidemiology

Fecal incontinence (FI) is the recurrent uncontrolled passage of fecal material, of 1 month or greater duration, in an individual with a developmental age of at least 4 years.<sup>1</sup> Community-based surveys have fostered increasing awareness of the symptom and its detrimental impact on lifestyle and functioning; these consequences are disproportionately severe compared with the medical consequences of FI (Table 13.1).<sup>2</sup> Physicians may under-recognize the prevalence and devastating consequences of FI, perhaps because patients are often embarrassed to discuss the symptom.

**Table 13.1** Epidemiology of fecal incontinence

Prevalence of FI in the community ranges from 2% to 15%.

Varying prevalence rates may be attributable to differences in survey techniques, definition of FI and population surveyed.

Prevalence is similar in men and women. Prevalence and severity of FI increased with aging; 47% of nursing home residents in one survey had FI.

Patients with FI are often embarrassed to discuss the symptom with a physician or friends.

FI affects quality of life in >50% of patients. FI may jeopardize employment, and may lead to institutionalization.

### Fecal incontinence: key features

- 1 Distressing symptom attributable to one or more disordered continence mechanisms.
- 2 Most patients have internal and/or external sphincter weakness. Rectal sensory disturbances (i.e. increased or reduced) and altered bowel habits (i.e. constipation and/or diarrhea) are also important.
- 3 Common causes include anal sphincter injury resulting from obstetric or iatrogenic trauma and/or pudendal neuropathy caused by obstetric injury or chronic straining.
- 4 Patients are often embarrassed to discuss the symptom with a physician.
- 5 Careful characterization of symptoms is useful for gauging severity, understanding pathophysiology and guiding management.
- 6 Diagnostic testing is guided by clinical features. Anal manometry and ultrasound are used to evaluate sphincter function and structure, respectively. Endoscopy necessary if mucosal disease process is a consideration.
- 7 Simple measures are often helpful: empathy, patient education, management of altered bowel habits and biofeedback therapy (for sphincter tone and/or rectal sensation).
- 8 Long-term success rate after surgical repair of anal sphincter defects is poor. More invasive approaches (e.g. graciloplasty) involve considerable morbidity.
- 9 Colostomy may be the only option for patients with symptoms refractory to other measures.

**Table 13.2** Anorectal factors maintaining continence

Factor (method of assessment)*	Physiological functions	Pathophysiology
Internal anal sphincter (anal manometry)	Smooth muscle responsible for maintaining ~70% resting anal tone. Resting tone is maintained by myogenic factors and tonic sympathetic excitation. Relaxes during defecation.	Resting and squeeze pressures are ↓ in most women with FI. Conversely, high sphincter pressures may hinder evacuation, predisposing to FI in some men.
External anal sphincter [anal manometry, <i>anal EMG</i> (for neural integrity)]	Tonically-active striated muscle which predominantly contains type I (slow-twitch) fibers in humans. Maintains ~30% of resting anal tone. Voluntary or reflex contraction (i.e. squeeze response) closes the anal canal, preserving continence.	Internal and external sphincter weakness is often caused by sphincter trauma. Obstetric or iatrogenic injuries are common causes of sphincter trauma. Diseases affecting upper or lower motor neuron pathways can also weaken the external sphincter.
Puborectalis (evacuation proctography, <i>dynamic pelvic MRI</i> )	Maintains a relatively acute anorectal angle at rest. Contracts further to preserve continence during squeeze.	MRI reveals puborectalis atrophy and/or impaired function in a subset of incontinent patients.
Rectal compliance ( <i>barostat testing</i> )	By relaxing (i.e. accommodating), the rectum can hold more stool until defecation is convenient.	Rectal compliance is ↓ in ulcerative and ischemic proctitis. Rectal capacity is ↓ in 'idiopathic' FI.
Rectal sensation (perception of latex balloon distension, <i>barostat testing</i> )	Rectal distension evokes the desire to defecate and is also critical for initiating the squeeze response when continence is threatened.	↓ rectal sensation occurs in FI, may impair evacuation and continence, and can be ameliorated by biofeedback therapy. Rectal sensation may contribute to the symptom of urgency in FI.
Anal sensation ( <i>electrosensitivity, temperature change</i> )	The exquisitely sensitive anal mucosa will periodically sample and ascertain whether rectal contents are gas, liquid or stool <sup>38</sup> when the anal sphincters relax.	The extent to which normal or disordered anal sampling reflexes contribute to fecal continence or FI respectively are unclear.

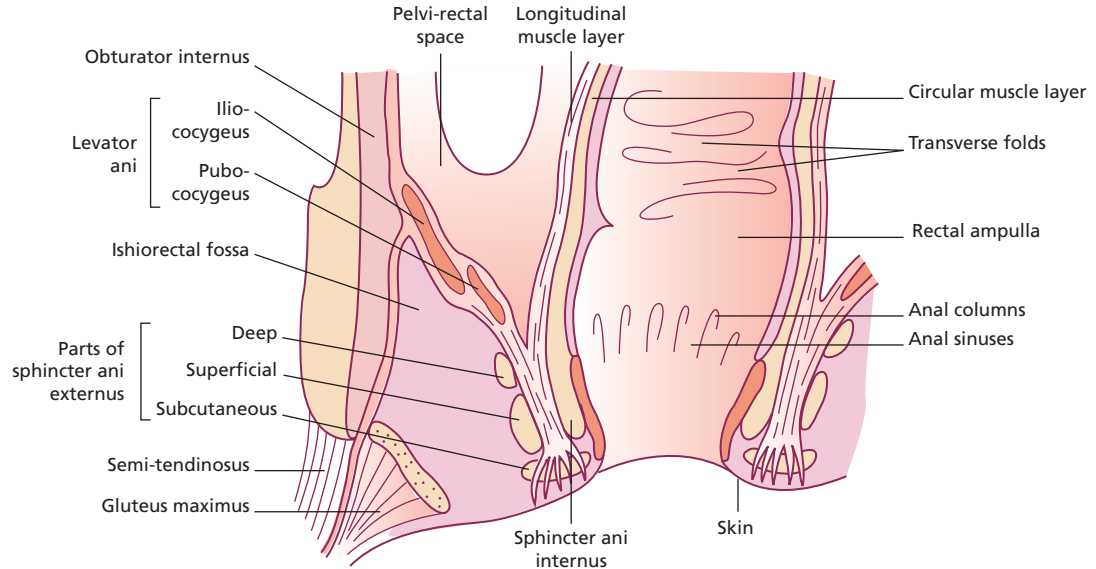
\*Italics indicate the test is used in research studies but is not widely available or generally used in clinical practice. ↓ = reduced; ↑ = increased.

### Mechanisms of normal and disordered continence

Fecal continence is maintained by anatomical factors, rectal compliance and recto-anal sensation (Table 13.2). Anatomical factors include the anal sphincters and levator ani (i.e. the pelvic floor), rectal curvatures and transverse rectal folds (Fig. 13.1). The rectum is a distensible organ that relaxes, allowing defecation to be postponed until convenient. The perception of rectal distension is indispensable for defecation and for voluntary contraction of the pelvic floor when continence is threatened (Fig. 13.2). Moreover, disturbances of stool consistency, mental facul-

ties, and mobility often contribute to FI, particularly in patients who have impaired anorectal continence mechanisms.

Anal sphincter pressures are reduced in most, but not all, incontinent patients.<sup>3</sup> However, anal sphincter pressures do not always distinguish continent from incontinent subjects, underscoring the importance of rectal compliance and sensation in maintaining continence. Impaired rectal sensation allows the stool to enter the anal canal and perhaps leak before the external sphincter contracts.<sup>3,4</sup> On the other hand, exaggerated rectal sensation, perhaps a marker of coexistent irritable bowel syndrome,<sup>5</sup> is associated



**Fig. 13.1** Diagram of a coronal section of the rectum, anal canal and adjacent structures. The pelvic barrier includes the anal sphincters and pelvic floor muscles. Reproduced

with permission from Bharucha AE. Fecal incontinence. *Gastroenterology* 2003; **124**: 1672–85.

with reduced rectal compliance, repetitive rectal contractions during rectal distension, external sphincter weakness and exaggerated anal sphincter relaxation during rectal distension.<sup>3</sup> Thus, FI is a heterogeneous disorder, patients often suffering from more than one deficit (Table 13.3).

### Etiology

FI is attributable to conditions associated with pelvic floor weakness and/or diarrhea (Table 13.4). Before the advent of endoanal ultrasound, unexplained sphincter weakness was considered ‘idiopathic’, or attributed to a pudendal neuropathy. Endoanal ultrasound revealed clinically occult internal and external anal sphincter injury in FI and after vaginal delivery in women.<sup>6,7</sup> However, the median age of onset of ‘idiopathic’ FI is ~ 61 years; that is, several decades after vaginal delivery. This suggests that, in addition to anal sphincter trauma caused by vaginal delivery, other factors – as yet poorly defined, but including aging, menopause, chronic straining, and disordered bowel habits – probably predispose to FI.

The prevalence of FI increases with age and anorectal functions decline with age. Anal pressures are lower in older than in younger, asymptomatic men and women.

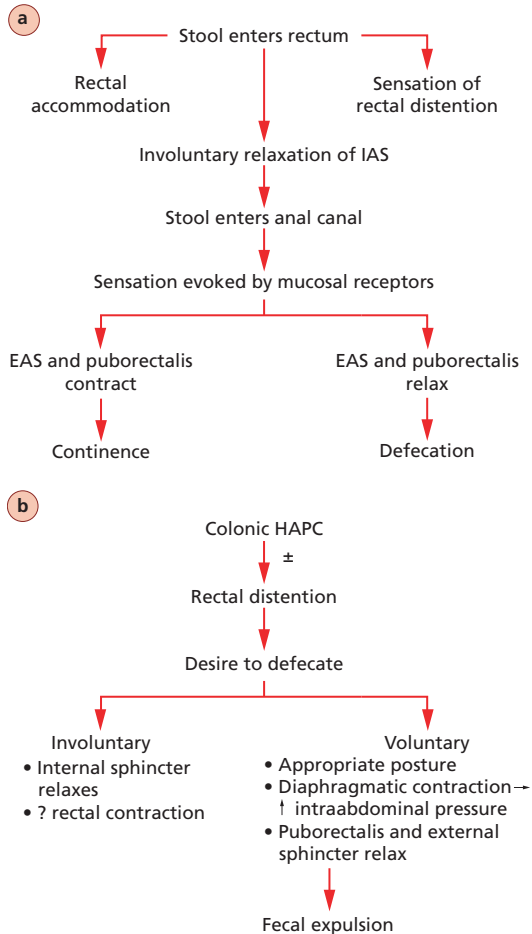
It is unknown if these effects are attributable to aging alone and/or hormonal changes associated with aging (e.g. menopause) and/or other confounding factors (e.g. obstetric trauma). Previous studies suggested that anal resting and squeeze pressures were lower in older than in younger subjects.<sup>8,9</sup> We recently demonstrated that anal resting pressures did, but squeeze pressures did not decline with age in carefully selected asymptomatic women without other risk factors for pelvic floor trauma.<sup>10</sup> The relative sparing of anal squeeze pressures by aging is consistent with the muscle fiber distribution in the human external anal sphincter. The human external anal sphincter predominantly contains type I (i.e. slow twitch) fibers, which, in contrast to type II fibers, are relatively spared by aging.<sup>11</sup> Rectal compliance also declined with age in asymptomatic women.<sup>10</sup> Taken together, the evidence indicates that reduced anal resting pressure and reduced rectal compliance may predispose to FI.

In men, FI is often attributable to local causes, such as anal fistulae, poorly healed surgical scars or proctitis after radiotherapy for prostate cancer. Idiopathic fecal soiling or leakage in men may also be caused by a long anal sphincter of high pressure that entraps small particles of feces during defecation and subsequently

**Table 13.3** Anorectal sensorimotor disturbances in fecal incontinence

Etiology	Anal sphincter pressures	Threshold for internal sphincter relaxation	Threshold for external sphincter contraction	Rectal sensation*	Rectal compliance	Pelvic floor function
Idiopathic	↓	↓	↓	↓ or ↑	↓ or ↑	↓
Diabetes mellitus <sup>39</sup>	R ↓; S ↓	↔	NA	↓↓	↔	NA
Multiple sclerosis <sup>39</sup>	R ↔; S ↓↓	↓	NA	↓↓	↔	NA
Elderly patients with fecal impaction and incontinence <sup>40</sup>	R ↔; S ↔	↓	NA	↓	NA	↓
Acute radiation proctitis <sup>41</sup>	R ↓; S ↓	NA	NA	↔	↓	NA
Chronic radiation injury <sup>42</sup>	NA	NA	NA	↓	↓	NA
Ulcerative colitis <sup>43</sup>	S ↓ in FI	↓ (active colitis only)	NA	↑ (active colitis only)	↑ (active colitis only)	NA
Spinal cord injury – high spinal lesion, i.e. T12 or higher <sup>18</sup>	R ↔; S ↓	↓	↔	↓	↓	NA
Low spinal lesion, i.e. below T12	R ↓; S ↓	↔	↓	↓	↔	NA

Information pertains to patients with underlying disease and FI. ↑ = Increased; ↓ = decreased; ↔ = no change. R = resting; S = squeeze sphincter pressure; NA = not available. \* Rectal sensation expressed as volume thresholds for perception; ↑ sensation indicates volume threshold for perception was lower than in normals. Reproduced with permission from Bharucha AE. Fecal incontinence. *Gastroenterology* 2003; **124**: 1672–85.



**Fig. 13.2** Schematic of events that accompany fecal continence (a) and defecation (b). HAPC, high-amplitude propagated contraction. Panel b is reproduced with permission from Bharucha AE, Camilleri M. Physiology of the colon. In: Pemberton JH, ed. *Shackelford's Surgery of the Alimentary Tract, Vol. IV. The Colon*. 5th edn. Philadelphia: WB Saunders, 2001: 29–39. IAS, internal anal sphincter. EAS, external anal sphincter.

expels them, causing perianal soiling and discomfort.<sup>12</sup> Approximately 5% of patients develop chronic anorectal complications (fistula, stricture and disabling FI) after pelvic radiotherapy.<sup>13</sup> Surgical procedures that may contribute to FI include sphincterotomy and fistulotomy. Postoperative FI affects about 45% of patients after a lateral internal sphincterotomy; 6%, 8% and 1% reported incontinence to flatus, minor fecal soiling and loss of solid stool, respectively, 5 years thereafter.<sup>14</sup>

The risk of FI after a fistulotomy has been reported to range from 18 to 52%, but is perhaps lower with recent modifications.<sup>15</sup>

Several neurological disorders are associated with FI (Table 13.4). Anal sphincter weakness, diminished rectoanal sensation and diarrhea predispose to FI in patients with diabetic neuropathy. Impairment of anorectal function generally parallels the duration of disease.<sup>16</sup> Fifty-one percent of a group of unselected outpatients with multiple sclerosis had FI.<sup>17</sup> Constipation is the predominant symptom after supraconal spinal cord injury; anal resting pressure is relatively preserved and FI is relatively uncommon. In contrast, resting anal sphincter tone is often reduced in patients with spinal cord lesions at or below T<sub>12</sub>; reduced anal sphincter tone, blunted recto-anal sensation<sup>18</sup> and laxatives predispose to FI in patients with lumbosacral lesions.

### Clinical evaluation

A meticulous clinical assessment is necessary to identify the etiology and pathophysiology of FI, establish rapport with the patient, and guide diagnostic testing and treatment. Terms used to reflect the nature and severity of FI include 'staining', 'seepage' (leakage of small amounts of stool) and 'soiling' (of clothes or bedding).

**Table 13.4** Etiology of fecal incontinence

#### Anal sphincter weakness

*Injury:* obstetric trauma related to surgical procedures, e.g. hemorrhoidectomy, internal sphincterotomy, fistulotomy, anorectal infection

*Non-traumatic:* scleroderma, internal sphincter thinning of unknown etiology

#### Neuropathy

Stretch injury, obstetric trauma, diabetes mellitus

#### Anatomical disturbances of the pelvic floor

Fistula, rectal prolapse, descending perineum syndrome

#### Inflammatory conditions

Crohn's disease, ulcerative colitis, radiation proctitis

#### Central nervous system disease

Dementia, stroke, brain tumors, spinal cord lesions, multiple system atrophy (Shy-Drager syndrome), multiple sclerosis

#### Diarrhea

Irritable bowel syndrome, post-cholecystectomy diarrhea

Reproduced with permission from Bharucha AE. Fecal incontinence. *Gastroenterology* 2003; **124**: 1672–85.

Scales for rating the severity of FI incorporate the nature and frequency of stool loss, number of pads used, severity of urgency, and the impact of FI on coping mechanisms and/or lifestyle-behavioral changes.<sup>19</sup> Quality of life includes not only items connected with coping, behavior, self-perception and embarrassment, but also practical day-to-day limitations, such as the ability to socialize and get out of the house.<sup>20</sup> Patients are affected even by the possibility and unpredictability of incontinence episodes. Thus, the type and frequency of incontinence episodes alone may underestimate the severity of FI in people who are housebound because of FI.

The clinical history provides several insights into the pathophysiology of FI (Table 13.5). The importance of carefully characterizing bowel habits cannot be overemphasized. Stool form and consistency can be described by pictorial stool scales.<sup>21</sup> The terms ‘urge FI’ and ‘passive FI’ refer to exaggerated and reduced awareness of the desire to defecate before the incontinence episode, respectively.

A multisystem examination should be guided by the history and by knowledge of underlying diseases. The positive predictive value of digital rectal examination for identifying low resting and squeeze pressures is 67 and 81%, respectively.<sup>22</sup> A digital rectal examination can also evaluate voluntary puborectalis contraction, manifest as normal upward and anterior movement of the puborectalis (i.e. a ‘lift’) when the subject squeezes. Examination in the seated position on a commode may be more accurate than the left lateral decubitus position for characterizing rectal prolapse, pouch of Douglas hernia or excessive perineal descent.

### Diagnostic testing

The extent of diagnostic testing is tailored to the patient’s age, probable etiological factors, symptom severity, impact on quality of life and response to conservative medical management. The strengths and limitations of these tests have been detailed elsewhere.<sup>7</sup> Endoscopy to identify mucosal pathology is probably

**Table 13.5** The clinical history in fecal incontinence: insights into pathophysiology

Question	Rationale
Onset, natural history and risk factors	Relationship of symptom onset/deterioration to other illnesses may suggest etiology. Natural history may reveal why a patient has sought medical attention.
Bowel habits/ type of leakage	Semiformed or liquid stools, perhaps resulting from laxative use in constipated patients, pose a greater threat to pelvic floor continence mechanisms than formed stools. Incontinence for solid stool suggests more severe sphincter weakness than incontinence for liquid stool only. Management should be tailored to specific bowel disturbance.
Degree of warning before FI	Urge and passive FI are associated with more severe weakness of the external and internal anal sphincter, respectively. These symptoms may also reflect rectal sensory disturbances, potentially amenable to biofeedback therapy.
Diurnal variation in FI	Nocturnal FI occurs uncommonly in idiopathic FI and is most frequently encountered in diabetes and scleroderma.
Urinary incontinence – presence and type	Association between urinary and FI. Same therapy may be effective for both conditions.
Evaluate possible causes of FI	Multisystem diseases causing FI are generally evident on a history and physical examination. The obstetric history must inquire specifically for known risk factors for pelvic trauma, e.g. forceps delivery, episiotomy, and prolonged second stage of labor. Medications (e.g. laxatives, artificial stool softeners) may cause or exacerbate FI.

Modified with permission from Bharucha AE. Fecal incontinence. *Gastroenterology* 2003; **124**: 1672–85.

necessary for FI patients with significant, particularly recent-onset diarrhea or constipation. The extent of examination (sigmoidoscopy or colonoscopy) and consideration of mucosal biopsies are guided by the patient's age, comorbidities and differential diagnosis. The indications for, and extent of, diagnostic testing in FI are evolving. For ambulatory, otherwise healthy patients, anorectal manometry and endoanal ultrasound are useful to document severity of weakness and to identify abnormal sphincter morphology, respectively. Evacuation proctography may be useful to characterize puborectalis contraction, confirm a coexistent evacuation disorder, and/or document the severity of clinically suspected excessive perineal descent or a rectocele. Endoanal MRI is useful for visualizing anal sphincter morphology, particularly external sphincter atrophy (Fig. 13.3), while dynamic MRI can concurrently image the bladder, genital organs and anorectum in real time without radiation exposure (Figs 13.4 and 13.5). However, pelvic MRI is relatively expensive and not widely available. Anal sphincter EMG should be considered for incontinent patients with an underlying disease associated with a neuropathy, such as diabetes mellitus, clinical suspicion of a proximal neurogenic process, or sphincter weakness unexplained by morphology as visualized

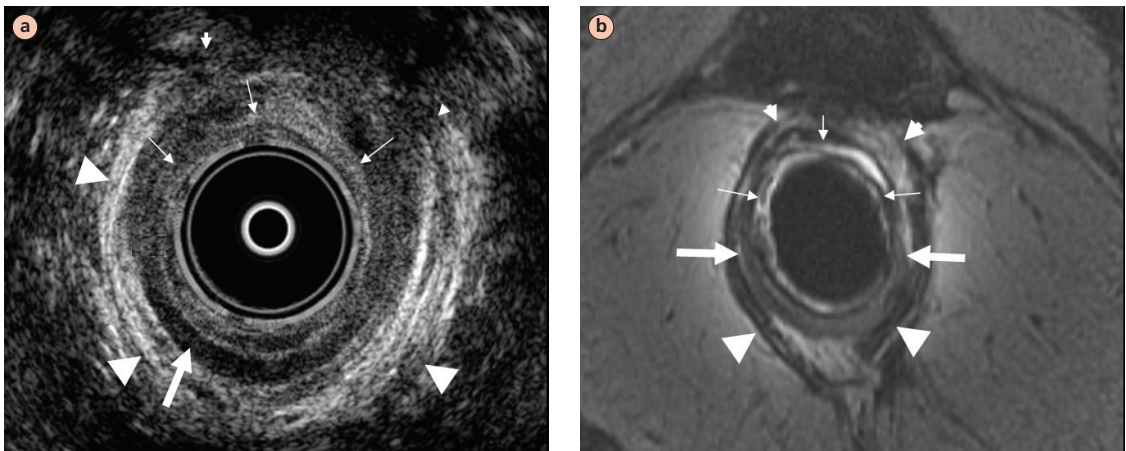
by ultrasound. Delayed pudendal nerve terminal motor latencies (PNTML) are widely used as a surrogate marker for pudendal neuropathy. Initial studies suggested that patients with a pudendal neuropathy would not fare as well after surgical repair of sphincter defects compared with patients without a neuropathy. However, the accuracy of delayed PNTML as a marker for pudendal neuropathy has been questioned on several grounds.<sup>23</sup> The test measures only conduction velocity in the fastest conducting nerve fibers, and there are inadequate normative data. Test reproducibility is unknown, and sensitivity and specificity are poor. In fact, in contrast to initial studies, recent studies suggest that the test does not predict improvement, or lack thereof, after surgical repair of anal sphincter defects.

### Management

The management must be tailored to clinical manifestations, and includes treatment of underlying diseases, and other approaches detailed in Table 13.6.

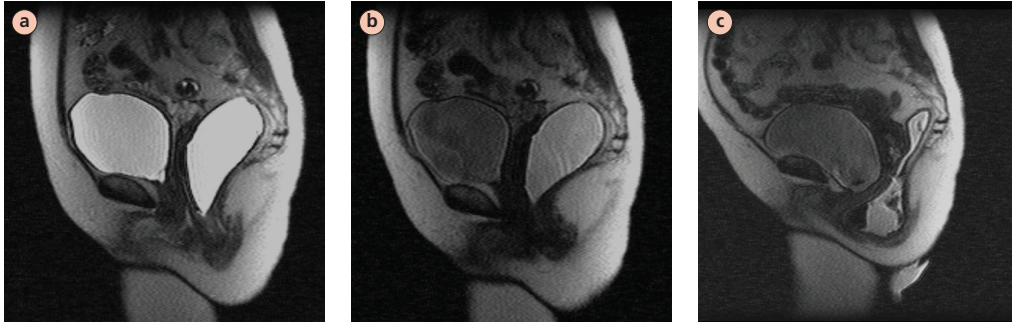### Modification of bowel habits

Modification of bowel habits by simple measures is often extremely effective in managing FI. By taking loperamide or diphenoxylate before social occasions



**Fig. 13.3** Endoanal ultrasonographic (US; a) and magnetic resonance (MR) images (b) of anal sphincters in a patient with fecal incontinence. The internal anal sphincter is hypoechoic on the US image, while on the MR the internal sphincter is of higher signal intensity than the external sphincter. Thick and thin white arrows indicate normal internal sphincter and

tear, respectively (located approximately between 10 and 5 o'clock) on US and MR images. Large and small arrowheads indicate normal-appearing and partially torn external sphincter (between 10 and 2 o'clock), respectively. Reproduced with permission from Bharucha AE. Fecal incontinence. *Gastroenterology* 2003; **124**: 1672–85.

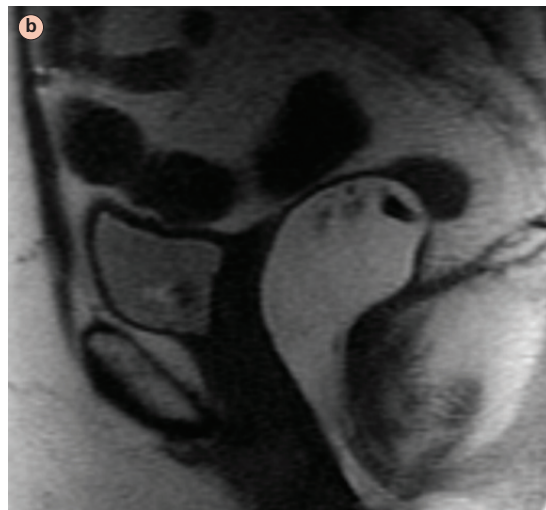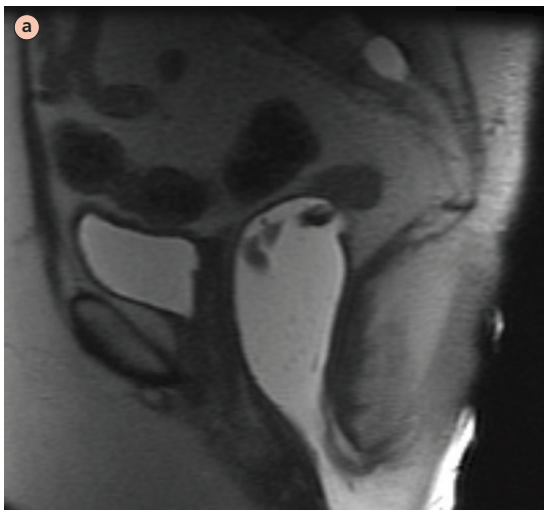


**Fig. 13.4** Magnetic resonance fluoroscopic images of the pelvis at rest (a), during squeeze (b), and simulated defecation (c) in a 52-year-old asymptomatic subject after filling the rectum with ultrasound gel. At rest, the pelvic floor was well supported and the anorectal angle measured  $126^\circ$ . Pelvic floor contraction during the squeeze maneuver was accompanied by normal upward and anterior motion of the anorectal junction; the angle declined to  $95^\circ$ . Rectal evacuation was associated with

relaxation of the puborectalis, as evidenced by opening of the anorectal junction, widening of the anorectal angle and perineal descent. The bladder base dropped by 2.5 cm below the pubococcygeal line; the 2.8 cm anterior rectocele emptied completely, and was probably not clinically significant; perineal descent (5 cm) was outside the normal range for evacuation proctography. Reproduced with permission from Bharucha AE. Fecal incontinence. *Gastroenterology* 2003; **124**: 1672–85.

or meals outside the home, incontinent patients may avoid having an accident outside the home and gain confidence in their ability to participate in social activities. The serotonin ( $5\text{-HT}_3$ ) antagonist alosetron (Lotronex<sup>TM</sup>, GlaxoSmithKline), available under a restricted use program in the USA, is an alternative option when functional diarrhea cannot be controlled by

other agents. Patients with constipation, fecal impaction and overflow FI may benefit from a regularized evacuation program, incorporating timed evacuation by digital stimulation and/or bisacodyl/glycerol suppositories, fiber supplementation, and selective use of oral laxatives, as detailed in a recent review.<sup>24</sup>



**Fig. 13.5** Pelvic magnetic resonance fluoroscopic images at rest (a) and squeeze (b) in a 57-year-old lady with FI. During squeeze, the puborectalis indentation on the posterior rectal wall was exaggerated compared with rest, and the anorectal

angle declined from  $143^\circ$  at rest to  $90^\circ$  during squeeze; however, the anal canal remained patulous. Reproduced with permission from Bharucha AE. Fecal incontinence. *Gastroenterology* 2003; **124**: 1672–85.

**Table 13.6** Management of fecal incontinence

Intervention	Side-effects	Comments	Mechanism of action
Incontinence pads*	Skin irritation	Disposable products provide better skin protection than non-disposable products; underpad products were slightly cheaper than body-worn products	Provide skin protection and prevent soiling of linen; polymers conduct moisture away from the skin
<b>Antidiarrheal agents*</b> Loperamide (Imodium) up to 16 mg/day in divided doses Diphenoxylate 5 mg q.i.d.	Constipation	Titrate dose; administer before meals and social events	↑ fecal consistency, ↓ urgency; ↑ anal sphincter tone
<b>Enemas***</b>	Inconvenient; side-effects of specific preparations		Rectal evacuation decreases likelihood of FI
<b>Biofeedback therapy</b> using anal canal pressure or surface EMG sensors; ** <sup>28</sup> rectal balloon for modulating sensation		Prerequisites for success include motivation, intact cognition, absence of depression, and some rectal sensation	Improved rectal sensation and coordinated external sphincter contraction ± anal sphincter tone
<b>Sphincteroplasty</b> for sphincter defects** <sup>29</sup>	Wound infection; recurrent FI (delayed)	Restricted to isolated sphincter defects without denervation	Restore sphincter integrity
<b>Sacral nerve stimulation**</b>	Infection	Preliminary uncontrolled trials promising	Unclear; ↑ anal sphincter tone may modulate rectal sensation
Artificial sphincter, gracilis transposition**	Device erosion, failure and infection	Either artificial device or gracilis transposition with/without electrical stimulation	Restore anal barrier

\*Grade A, \*\*grade B, \*\*\*grade C therapeutic recommendations. Grades A or B are supported by at least one randomized controlled trial, or one high-quality study of non-randomized cohorts. Grade C recommendations are expert opinions generally derived from basic research, applied physiological evidence or first principles, in controlled or randomized trials. ↑ = increased; ↓ = reduced; ± = possible. Adapted from Bharucha AE, Camilleri M. GI dysmotility and sphincter dysfunction. In: Noseworthy JH, ed. *Neurological Therapeutics: Principles and Practice*. London: Martin Dunitz (in press).

### Pharmacological approaches

Phenylephrine, an  $\alpha_1$ -adrenergic agonist, applied to the anal canal increased anal resting pressure by 33% in healthy subjects and in FI. However, phenylephrine did not significantly improve incontinence scores or resting anal pressure compared with placebo in a randomized, double-blind, placebo-controlled crossover study of 36 patients with FI.<sup>25</sup>

### Biofeedback therapy

Biofeedback is based on the principle of operant conditioning. Using a rectal balloon–anal manometry

device, patients are taught to contract the external anal sphincter when they perceive balloon distension. Perception may be reinforced by visual tracings of balloon volume and anal pressure, and the procedure is repeated with progressively smaller volumes. In uncontrolled studies, continence improved in about 70% of patients with FI. Though resting and squeeze pressures increased to a variable degree after biofeedback therapy, the magnitude of improvement was relatively small and not correlated to symptom improvement.<sup>26</sup> Perhaps these modest effects are attributable to inadequate biofeedback therapy, lack of reinforcement, and

assessment of objective parameters at an early stage after biofeedback therapy. In contrast, sensory assessments, i.e. preserved baseline sensation and improved sensory discrimination after biofeedback therapy, are more likely to be associated with improved continence after biofeedback therapy.<sup>27</sup>

A recent study randomized 171 FI patients to four groups: standard medical/nursing care (i.e. advice only); advice plus verbal instruction on sphincter exercises; hospital-based computer-assisted sphincter pressure biofeedback; and hospital biofeedback plus use of a home EMG biofeedback device.<sup>28</sup> Symptoms improved in approximately 50% of patients in all four groups, and improvement was sustained 1 year after therapy. These results underscore the importance patients attach to understanding the condition, practical advice regarding coping strategies (e.g. diet and skin care), and nurse–patient interaction.

### Surgical approaches

Continence improved in up to 85% of patients with sphincter defects after an overlapping anterior sphincteroplasty. For reasons that are unclear, continence deteriorates thereafter. Less than 50% of patients are continent 5 years after the operation.<sup>29</sup> Dynamic graciloplasty and artificial anal sphincter procedures are restricted to a handful of centers worldwide and are

often complicated by infections and device problems which may require reoperation, including removal of the device. A colostomy is the last resort for patients with severe FI.

### Minimally invasive approaches

Sacral nerve stimulation is an FDA-approved device that has been implanted in more than 3000 patients with urinary incontinence in the USA. Observations from European studies suggest that sacral nerve stimulation augments squeeze pressure more than resting pressure, may also modulate rectal sensation, and significantly improves continence.<sup>30</sup> Sacral stimulation is conducted as a staged procedure. Patients whose symptoms respond to temporary stimulation over about 2 weeks proceed to permanent subcutaneous implantation of the device. The procedure for device placement is technically straightforward, and device-related complications are less frequent or significant relative to more invasive artificial sphincter devices discussed above.

## Rectal evacuation disorders

### Pathophysiology

Rectal evacuation disorders are defined by symptoms of difficult defecation caused by a functional disorder

### Rectal evacuation disorders: key features

- 1 Normal rectal evacuation involves increased intra-abdominal pressure coordinated with pelvic floor relaxation.
- 2 Rectal evacuation disorders are defined by symptoms of difficult defecation caused by a functional disorder of the process of rectal evacuation.
- 3 Most attention has focused on pelvic floor dyssynergia, i.e. impaired relaxation of the puborectalis and/or external anal sphincter during defecation. Other causes include descending perineum syndrome and inadequate propulsive forces.
- 4 Symptoms: excessive straining and/or anal digitation and/or sense of anorectal blockage during defecation; sense of incomplete evacuation after defecation; infrequent defecation; hard stools.
- 5 A careful rectal examination is invaluable.
- 6 Rectal evacuation disorders cannot be distinguished from normal transit or slow transit constipation by symptoms alone.
- 7 Diagnostic tests: rectal balloon expulsion test (useful screening test); anal manometry; barium proctography; dynamic pelvic MRI.
- 8 Colonic transit is often delayed in rectal evacuation disorders.
- 9 Management: pelvic floor retraining by biofeedback therapy, judicious laxative use/psychological counseling if necessary.

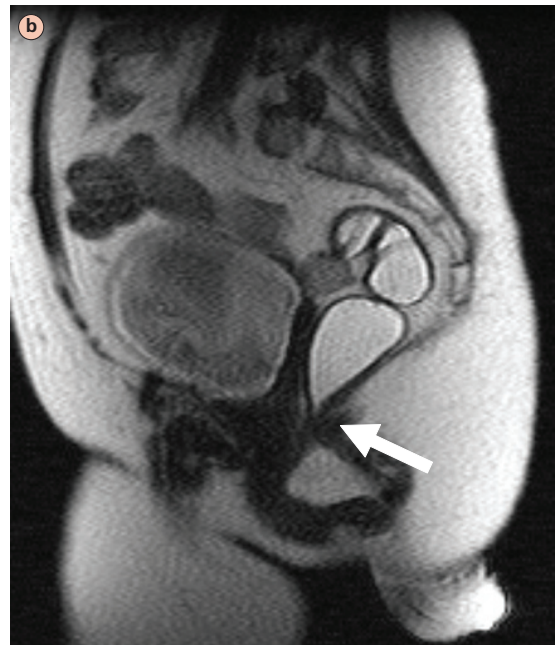
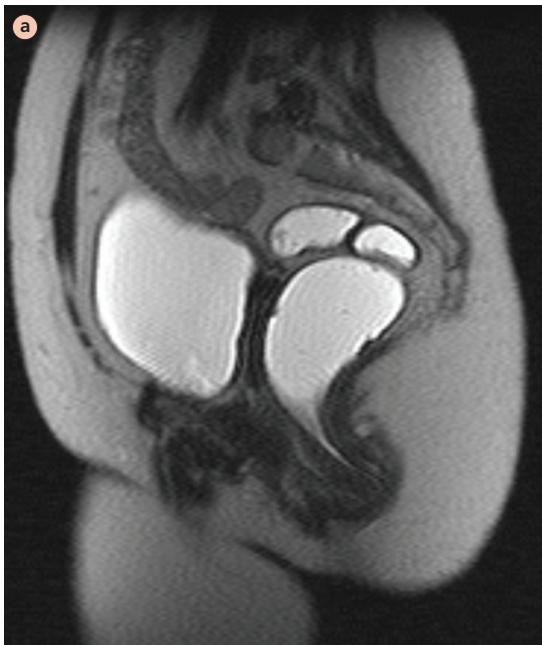
of the process of evacuation. The terms ‘anismus,’ ‘pelvic floor dyssynergia,’ ‘puborectalis spasm’ and ‘descending perineum syndrome’ reflect the phenotypic spectrum of rectal evacuation disorders. Anismus reflects increased anal resting tone, while pelvic floor dyssynergia refers to failure of relaxation or paradoxical contraction of the puborectalis and/or external anal sphincter during defecation.<sup>31</sup> The descending perineum syndrome is a sequel of long-standing, excessive straining, which weakens the pelvic floor causing excessive perineal descent.<sup>32</sup> The fourth subgroup within this spectrum of rectal evacuation disorders includes patients who cannot generate the rectal forces necessary to expel stools.

Most attention has focused on pelvic floor dyssynergia or paradoxical sphincter contraction, which can be demonstrated by anal manometry, anal sphincter EMG or defecography (Fig. 13.6).<sup>31</sup> While paradoxical puborectalis contraction is associated with impaired rectal evacuation, the specificity of this finding has been questioned on two grounds. First, some patients with pelvic floor dyssynergia have normal rectal evacuation. Secondly, pelvic floor dyssynergia has been observed

in asymptomatic subjects, and in patients with FI or pelvic pain who do not have symptoms of obstructed defecation. Given the inherent limitations of trying to replicate normal defecation in a laboratory, these inconsistencies are not surprising and they underscore the importance of considering symptoms when diagnosing rectal evacuation disorders.<sup>33</sup>

With the exception of Parkinson’s disease and multiple sclerosis, rectal evacuation disorders are probably not caused by lesion(s) in the central nervous system. Pelvic floor dyssynergia is associated with anxiety and psychological distress. It is conceivable that psychological distress contributes to pelvic floor dyssynergia by increasing the level of skeletal muscle tension.

Up to 60% of patients with pelvic floor dyssynergia have impaired rectal sensation.<sup>33</sup> Since the desire to defecate is essential for initiating defecation, it is conceivable that diminished rectal sensation, perhaps attributable to a neuropathy, may cause obstructed defecation. Alternatively, reduced rectal sensation may be the result of a change in rectal capacity, or it may be



**Fig. 13.6** Pelvic MR fluoroscopic images at rest (a) and evacuation (b) in a lady with obstructed defecation. Observe the

increased impression of the puborectalis on the posterior rectal wall during evacuation (white arrow) compared with rest.

secondary to retained stool in the rectal vault in obstructed defecation.

Left colonic transit is delayed in up to two-thirds of patients with pelvic floor dyssynergia. It is unclear if delayed left colonic transit is secondary to activation of rectocolonic inhibitory reflexes by stool in the rectum, and/or to physical restriction to passage of stool through the colon, and/or to coexistent colonic motor dysfunction unrelated to obstructed defecation.

Rectal evacuation disorders are primarily attributed to disordered function. However, structural anomalies (e.g. rectoceles and excessive perineal descent) may coexist (Fig. 13.4). Rectoceles are relatively common in older women and infrequently obstruct defecation. On the contrary, clinically significant rectoceles often occur in patients with a primary rectal evacuation disorder and may be secondary to excessive straining.

Perineal descent during defecation is generally reduced in anismus and pelvic floor dyssynergia. However, long-standing, excessive straining can weaken the pelvic floor, causing excessive perineal descent.<sup>32</sup> Excessive perineal descent widens the anorectal angle and impairs the flap valve that normally maintains continence when intra-abdominal pressure increases. Excessive perineal descent has also been implicated as causing stretch-induced pudendal neuropathy. These consequences of excessive perineal descent may explain why patients with the descending perineum syndrome have constipation initially, progressing to FI later.

The mechanisms responsible for inadequate rectal propulsive forces are unclear.<sup>34</sup> Indeed, the relative contributions of abdominal wall motion and rectal contraction to rectal forces during normal defecation are not understood.

### Clinical features

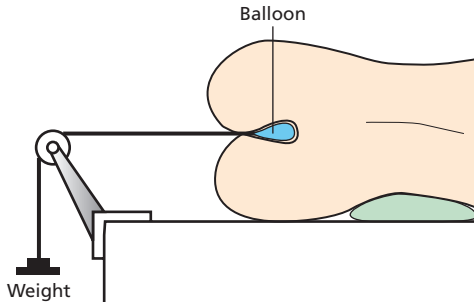
Symptoms include infrequent defecation, hard or lumpy stools, excessive straining during defecation, a sense of anal blockage during defecation, use of manual maneuvers to facilitate defecation and a sense of incomplete rectal evacuation after defecation. Anal pain during defecation and a sense of anal blockage are the only symptoms which occur more frequently in rectal evacuation disorders than in functional constipation.<sup>35,36</sup> However, it is not possible to discriminate between obstructed defecation, irritable bowel

syndrome and slow-transit constipation based on symptoms alone. The digital anal examination is often extremely useful for confirming a clinical suspicion of obstructed defecation. The examination may reveal prominent external hemorrhoids, an anal fissure, anismus (i.e. increased resistance to passage of the index finger in the anal canal), paradoxical contraction of the puborectalis during simulated defecation, and/or abnormal (i.e. increased or reduced) perineal descent during simulated defecation.

### Diagnostic tests

The Rome criteria for pelvic floor dyssynergia include evidence of impaired evacuation, adequate rectal propulsive forces and manometric, EMG or radiological evidence of paradoxical contraction, or failed relaxation of the anal sphincter during attempted defecation. The following considerations are pertinent to these assessments.

- *Increased resting anal pressure.* Though normal ranges are age-, gender- and technique-dependent, an average resting pressure greater than 100 mmHg is probably abnormal and suggestive of anismus.
- *Paradoxical increase in anal pressure during simulated defecation.* Since paradoxical anal sphincter contraction can also occur in asymptomatic subjects, test results must be considered in the overall clinical context.
- *Evacuation proctography* is useful for documenting impaired rectal evacuation, assessing the clinical significance of a rectocele and characterizing anorectal descent during simulated evacuation. Another, perhaps under-recognized, benefit of evacuation proctography is the ability to educate patients about the nature of their disorder by reviewing images with them. More recently, rapid MR imaging sequences have been developed to visualize pelvic floor motion in real time without radiation exposure.<sup>37</sup> The bony landmarks necessary to characterize anorectal motion are more readily visualized by MRI compared with evacuation proctography. Dynamic pelvic MRI can also evaluate urogenital and anorectal prolapse during the same examination.
- *The rectal balloon expulsion test* (Fig. 13.7). When compared with manometry and evacuation proctography, an abnormal balloon expulsion test was 88% sensitive (positive predictive value of 64%) and



**Fig. 13.7** Schematic of rectal balloon expulsion test. The subject is asked to expel a rectal balloon filled with 50 ml of warm water and connected over a pulley to a series of weights. Patients without pelvic floor dysfunction can expel the balloon with no or limited external rectal traction. Patients with pelvic floor dyssynergia require additional external traction to facilitate expulsion of the rectal balloon. Reproduced with permission from Bharucha AE, Klingele CJ. *Autonomic and somatic systems to the anorectum and pelvic floor*. In: Dyck PJ, Thomas PK, eds. *Peripheral Neuropathy*. 4th edn. Philadelphia: Elsevier, 2004.

89% specific (negative predictive value of 97%) for diagnosing pelvic floor dyssynergia.<sup>36</sup> Thus, a normal rectal balloon expulsion test is extremely useful for excluding pelvic floor dyssynergia in constipated patients.

- *Colonic transit* is often delayed in obstructed defecation. Therefore, it is necessary to exclude obstructed defecation before making a primary diagnosis of slow transit constipation in patients with delayed colonic transit (Fig. 13.6).

### Management

Pelvic floor retraining by biofeedback therapy is the cornerstone for managing obstructed defecation. In uncontrolled studies, symptoms improved after pelvic floor retraining in 70% of patients with obstructed defecation; controlled studies are in progress. Pelvic floor retraining facilitates pelvic floor relaxation, and improves coordination between abdominal wall and diaphragmatic contraction and pelvic relaxation during defecation. There is limited objective evidence of improved pelvic floor function after biofeedback therapy. The specific protocols for biofeedback training vary between centers. It is important to concurrently address dietary imbalances (e.g. eating disorders) and psychological disturbances during pelvic floor retraining. Since stool size and consistency influence the ease

of defecation, fiber supplements and judiciously used osmotic laxatives are often necessary.

### Functional anorectal pain

The Rome diagnostic criteria have maintained the historical characterization of functional anorectal pain as levator ani syndrome and proctalgia fugax.<sup>33</sup> The pathophysiology of these disorders is poorly understood. The often-stated differences in the clinical features of these disorders (Table 13.7) may be blurred in clinical practice.

### Acknowledgment

This work was supported in part by USPHS NIH grants RO1 HD 38666 and HD 41129.

### References

- 1 Whitehead WE, Wald A, Norton NJ. Treatment options for fecal incontinence. *Dis Colon Rectum* 2001; **44**: 131–42 [discussion 142–4].
- 2 Perry S, Shaw C, McGrother C *et al*. Prevalence of faecal incontinence in adults aged 40 years or more living in the community. *Gut* 2002; **50**: 480–4.
- 3 Sun WM, Donnelly TC, Read NW. Utility of a combined test of anorectal manometry, electromyography, and sensation in determining the mechanism of ‘idiopathic’ faecal incontinence. *Gut* 1992; **33**: 807–13.
- 4 Buser WD, PB Miner Jr. Delayed rectal sensation with fecal incontinence. Successful treatment using anorectal manometry. *Gastroenterology* 1986; **91**: 1186–91.
- 5 Whitehead WE, Palsson OS. Is rectal pain sensitivity a biological marker for irritable bowel syndrome: psychological influences on pain perception. *Gastroenterology* 1998; **115**: 1263–71.
- 6 Sultan AH, Kamm MA, Hudson CN, Thomas JM, Bartram CI. Anal-sphincter disruption during vaginal delivery. *N Engl J Med* 1993; **329**: 1905–11.
- 7 Bharucha A. Fecal incontinence. *Gastroenterology* 2003; **124**: 1672–85.
- 8 Jameson JS, Chia YW, Kamm MA, Speakman CT, Chye YH, Henry MM. Effect of age, sex and parity on anorectal function. *Br J Surg* 1994; **81**: 1689–92.
- 9 McHugh SM, Diamant NE. Effect of age, gender, and parity on anal canal pressures. Contribution of impaired anal sphincter function to fecal incontinence. *Dig Dis Sci* 1987; **32**: 726–36.

**Table 13.7** Comparison of levator ani syndrome with proctalgia fugax

Clinical feature	Levator ani syndrome	Proctalgia fugax
Prevalence	Relatively common	Extremely rare
Pathophysiology	Unclear. Has been attributed to striated muscle 'tension'	Unclear. Smooth muscle spasm has been implicated. Hereditary form associated with internal anal sphincter hypertrophy
Nature of pain	Relatively chronic, dull, deep-seated rectal pain or urgency, lasting hours	Infrequent episodes (often <5 episodes/year) of relatively sharp, intermittent anal pain lasting seconds to minutes
Tenderness to palpation of puborectalis	Often present	Absent
Diagnostic testing	↑ resting anal pressure. Biofeedback therapy may reduce resting anal pressure and reduce pain	Unremarkable
Psychological issues	Elevated score on hypochondriasis, depression, and hysteria scales of MMPI, i.e. the 'neurotic triad' in chronic pain patients	Perfectionistic, anxious, and/or hypochondriacal traits in uncontrolled studies
Management	Uncontrolled studies – electrogalvanic stimulation, biofeedback therapy, digital massage of levator ani, sitz baths and muscle relaxants	Salbutamol inhalation abbreviated episodes in a controlled trial  Clonidine, amyl nitrate, or nitroglycerin also suggested

↑ = increased; ↓ = decreased; ↔ = no change. MMPI, Minnesota Multiphasic Personality Inventory.

- 10 Fox JC, Rath-Harvey D, Helwig PS, Zinsmeister AR, Bharucha AE. Anal sphincter pressures and rectal compliance decline with aging in asymptomatic women. *Gastroenterology* 2002; **122** (Suppl.): A-69.
- 11 Lexell J, Taylor CC, Sjöström M. What is the cause of the ageing atrophy? Total number, size and proportion of different fiber types studied in whole vastus lateralis muscle from 15- to 83-year-old men. *J Neurol Sci* 1988; **84**: 275–94.
- 12 Parellada CM, Miller AS, Williamson ME, Johnston D. Paradoxical high anal resting pressures in men with idiopathic fecal seepage. *Dis Colon Rectum* 1998; **41**: 593–7.
- 13 Hayne D, Vaizey CJ, Boulos PB. Anorectal injury following pelvic radiotherapy. *Br J Surg* 2001; **88**: 1037–48.
- 14 Nyam DC, Pemberton JH. Long-term results of lateral internal sphincterotomy for chronic anal fissure with particular reference to incidence of fecal incontinence. *Dis Colon Rectum* 1999; **42**: 1306–10.
- 15 Del Pino A, Nelson RL, Pearl RK, Abcarian H. Island flap anoplasty for treatment of transsphincteric fistula-in-ano. *Dis Colon Rectum* 1996; **39**: 224–6.
- 16 Epanomeritakis E, Koutsoumbi P, Tsiaoussis I *et al.* Impairment of anorectal function in diabetes mellitus parallels duration of disease. *Dis Colon Rectum* 1999; **42**: 1394–400.
- 17 Wiesel PH, Norton C, Glickman S, Kamm MA. Pathophysiology and management of bowel dysfunction in multiple sclerosis. *Eur J Gastroenterol Hepatol* 2001; **13**: 441–8.
- 18 Sun WM, Read NW, Donnelly TC. Anorectal function in incontinent patients with cerebrospinal disease. *Gastroenterology* 1990; **99**: 1372–9.
- 19 Vaizey CJ, Carapeti E, Cahill JA, Kamm MA. Prospective comparison of faecal incontinence grading systems. *Gut* 1999; **44**: 77–80.
- 20 Rockwood TH, Church JM, Fleshman JW *et al.* Fecal incontinence quality of life scale: quality of life instrument for patients with fecal incontinence. *Dis Colon Rectum* 2000; **43**: 9–16 [discussion 16–7].
- 21 Lewis SJ, Heaton KW. Stool form scale as a useful guide to intestinal transit time. *Scand J Gastroenterol* 1997; **32**: 920–4.
- 22 Hill J, Corson RJ, Brandon H, Redford J, Faragher EB, Kiff ES. History and examination in the assessment of patients with idiopathic fecal incontinence. *Dis Colon Rectum* 1994; **37**: 473–7.
- 23 American Gastroenterological Association. American Gastroenterological Association Medical Position Statement on

- Anorectal Testing Techniques. *Gastroenterology* 1999; **116**: 732–60.
- 24 Locke GR 3rd, Pemberton JH, Phillips SF. AGA technical review on constipation. American Gastroenterological Association. *Gastroenterology* 2000; **119**: 1766–78.
  - 25 Carapeti EA, Kamm MA, Phillips RK. Randomized controlled trial of topical phenylephrine in the treatment of faecal incontinence. *Br J Surg* 2000; **87**: 38–42.
  - 26 Bharucha AE. Outcome measures for fecal incontinence: anorectal structure and function. *Gastroenterology* 2004; **126**: S90–8.
  - 27 Wald A, Tunuguntla AK. Anorectal sensorimotor dysfunction in fecal incontinence and diabetes mellitus. Modification with biofeedback therapy. *N Engl J Med* 1984; **310**: 1282–7.
  - 28 Norton C, Hosker G, Brazzelli M. Biofeedback and/or sphincter exercises for the treatment of faecal incontinence in adults. *Cochrane Database Syst Rev* 2000: CD002111.
  - 29 Bachoo P, Brazzelli M, Grant A. Surgery for faecal incontinence in adults. *Cochrane Database of Syst Rev* 2000: CD001757.
  - 30 Rosen HR, Urbarz C, Holzer B, Novi G, Schiessel R. Sacral nerve stimulation as a treatment for fecal incontinence. *Gastroenterology* 2001; **121**: 536–41.
  - 31 Bharucha AE. Obstructed defecation: don't strain in vain! [comment]. *Am J Gastroenterol* 1998; **93**: 1019–20.
  - 32 Bartolo DC, Read NW, Jarratt JA, Read MG, Donnelly TC, Johnson AG. Differences in anal sphincter function and clinical presentation in patients with pelvic floor descent. *Gastroenterology* 1983; **85**: 68–75.
  - 33 Whitehead WE, Wald A, Diamant NE, Enck P, Pemberton JH, Rao SS. Functional disorders of the anus and rectum. *Gut* 1999; **45** (Suppl. 2): II55–9.
  - 34 Rao SS, Welcher KD, Leistikow JS. Obstructive defecation: a failure of rectoanal coordination. *Am J Gastroenterol* 1998; **93**: 1042–50.
  - 35 Grotz RL, Pemberton JH, Talley NJ, Rath DM, Zinsmeister AR. Discriminant value of psychological distress, symptom profiles, and segmental colonic dysfunction in outpatients with severe idiopathic constipation. *Gut* 1994; **35**: 798–802.
  - 36 Minguez M, Herreros B, Sanchiz V *et al.* Predictive value of the balloon expulsion test for excluding the diagnosis of pelvic floor dyssynergia in constipation. *Gastroenterology* 2004; **126**: 57–62.
  - 37 Fletcher JG, Busse RF, Riederer SJ *et al.* Magnetic resonance imaging of anatomic and dynamic defects of the pelvic floor in defecatory disorders. *Am J Gastroenterol* 2003; **98**: 399–411.
  - 38 Miller R, Bartolo DC, Cervero F, Mortensen NJ. Anorectal sampling: a comparison of normal and incontinent patients. *Br J Surg* 1988; **75**: 44–7.
  - 39 Caruana BJ, Wald A, Hinds JP, Eidelman BH. Anorectal sensory and motor function in neurogenic fecal incontinence. Comparison between multiple sclerosis and diabetes mellitus. *Gastroenterology* 1991; **100**: 465–70.
  - 40 Read NW, Abouzekry L. Why do patients with faecal impaction have faecal incontinence. *Gut* 1986; **27**: 283–7.
  - 41 Yeoh EK, Russo A, Botten R *et al.* Acute effects of therapeutic irradiation for prostatic carcinoma on anorectal function. *Gut* 1998; **43**: 123–7.
  - 42 Varma JS, Smith AN, Busuttill A. Correlation of clinical and manometric abnormalities of rectal function following chronic radiation injury. *Br J Surg* 1985; **72**: 875–8.
  - 43 Rao SS, Read NW, Davison PA, Bannister JJ, Holdsworth CD. Anorectal sensitivity and responses to rectal distension in patients with ulcerative colitis. *Gastroenterology* 1987; **93**: 1270–5.